

# Suture associated corneal abscess three years after cataract surgery: a case report

Wani G. Mena<sup>a</sup>

<sup>a</sup> Department of Ophthalmology, Juba Teaching Hospital, Juba, South Sudan

Email: [wanigmena@gmail.com](mailto:wanigmena@gmail.com)

## Abstract

We describe a case of corneal abscess presenting three years after uneventful cataract extraction with posterior chamber lens implantation through a limbal incision secured with three sutures placed in the clear cornea. After removing the abscess, a loose 10/0 nylon suture was found at the base of an ulcer. The suture was removed and a scraping taken from the base of the ulcer after which the patient was started on topical antibiotics and cycloplegics. Results of Gram stain microscopy were negative. After one month follow up, the ulcer had healed without perforation leaving a deep depression on the cornea. Risk factors and bacteriology of suture related corneal abscess are discussed and suture associated complications of cataract surgery are reviewed.

## Case report

A 47-year old housewife presented to the Eye Clinic at Juba Medical Complex, Juba County, Central Equatoria State with a one-week history of tearing, pain, photophobia and reduced vision in the left eye. She had an uneventful left extracapsular cataract extraction with posterior chamber lens implantation through a corneal incision in Khartoum Sudan, three years prior to the onset of the present symptoms. There was no history of trauma, and systemic enquiry revealed no diabetes mellitus or hypertension. She had been on topical steroid therapy until one month prior to presentation.

## Clinical assessment

On examination, visual acuity was OD 6/60 and OS 3/60. The right eye had a posterior subcapsular cataract. The left eye was inflamed with corneal oedema obscuring iris details. At the one o'clock position near the limbus there was a large cystic abscess filling a corneal depression 1.8 x 2mm in diameter (Figure 1). The ulcer edge was vascularized with vessels originating from the site of the suture on the limbus. Stromal infiltrates could be seen in the cornea surrounding the ulcer. The anterior chamber was deep with no hypopyon. The pupil was round and central. No posterior synechiae were noted. A posterior chamber lens was centred on the pupil. Refraction was OD -3.50/-0.50 Axis 60 and OS +4.75/-2.75

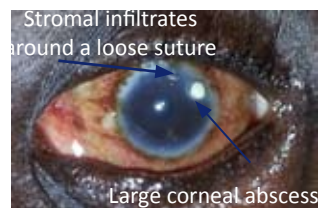


Figure 1. Left eye corneal abscess at 2 o'clock position close to the limbus (credit Wani Mena)

Axis 130. Visual acuity did not improve with correction. Fundoscopy revealed pale cupped discs with Cup:Disc ratio of 0.6 in the right eye.

## Treatment

The abscess was carefully removed on slit lamp using blunt tipped forceps without breaking the thin membrane covering it. There was a deep corneal depression at the bottom of which was found a loose 10/0 nylon corneoscleral suture. Another loose suture was present at the 12 o'clock position surrounded by stromal infiltrates. Both sutures were removed (Figure 2).

A corneal scraping was taken from the base and edges of the ulcer. Bacteriological examination of the smear was negative but culture facilities were unavailable. Topical gentamicin 0.3% and ciprofloxacin 0.3% was applied every four hours during the day and tobramycin ointment at night. Homatropine 1% twice daily was given to ease pain and prevent posterior synechiae. Combigan eye drops twice daily

were given to prevent glaucoma. The eye was patched and the patient followed up daily for the first week and then weekly.

At the end of the first week, visual acuity remained the same in both eyes but slit lamp biomicroscopic examination revealed a less inflamed eye with clearing of the corneal edema, resolution of the stromal infiltrates and thinning of the ulcer base. The patient was put on artificial tears, given an eye patch and asked to continue with antibiotics. Review after two weeks showed complete healing of the ulcer without perforation leaving a shallow depression on the cornea.

## Discussion

The technique of wound construction in cataract surgery has advanced tremendously from the traditional large 12 mm cataract wound closed with multiple sutures to small incision scleral tunnel and now to clear cornea self-sealing incision that guarantees minimum discomfort, better visual rehabilitation, faster postoperative recovery and minimum postoperative astigmatism. Coincident with these gains is an increasing incidence of post cataract surgery infections

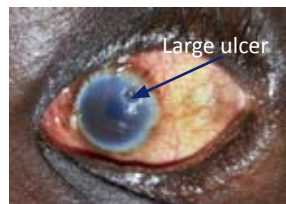


Figure 2. Large ulcer seen after removal of abscess (credit Wani Mena)

ranging from mild keratitis to endophthalmitis. These infections although rare are devastating as they can progress to endophthalmitis resulting in loss of vision or the whole eye.

Self-sealing clear corneal incisions are preferred by many surgeons performing phacoemulsification because of the short surgical time involved, avoidance of conjunctival trauma, reduction of post-surgery astigmatism and enhancement of post-operative recovery compared to scleral tunnel surgery [1]. Manual extracapsular cataract extraction and posterior chamber lens implantation through corneal or limbal incision requires suture to secure the integrity and security of the larger wound necessary for delivery of the nucleus in whole. Use of suture in clear cornea or limbal incision is attended with many problems including harbouring of bacteria by the suture which brings about local inflammation and necrosis. Exposed or broken sutures may cause foreign body sensation necessitating repeated visits to physician thereby increasing the cost of post-operative care. Loose sutures provide a tract through which bacteria may gain entry into the cornea.

Suture related corneal infections, including corneal abscess and endophthalmitis, have mainly been reported in patients undergoing penetrating keratoplasty [2, 3]. Some cases of suture related corneal infection complicating cataract surgery have also been reported in the literature [4, 5]. Suture related corneal abscess typically present as a delayed complication occurring months or even years after uneventful cataract surgery. Common incisions associated with suture related abscess include corneal and limbal incisions in which one end of the suture is placed in clear cornea

Unburied, loose or broken suture seems to confer risk for development of keratitis after cataract surgery [4]. Contact lens wear, use of topical steroids and history of Herpes Simplex Keratitis are additional risk factors that may predispose a patient to infection. The mechanism by which loose sutures induce keratitis are not well understood although it is thought that organisms adhere to the suture leading to formation of a biofilm that aids bacterial entry into the cornea through the suture tract

The most common organisms recovered from culture of + sutures recovered from such ulcers include *Staphylococcus aureus*, *Staphylococcus epidermidis* and *Streptococcus pneumoniae* [3, 6, 7, 8]. Takashi *et al* [2] isolated *Corynebacterium macginleyi* from a keratoplasty patient with suture related keratitis and argued that loose sutures made it easy for organisms to attach and migrate into the cornea.

The sources of organisms isolated in suture-related abscesses seem to be the eye lids or conjunctiva suggesting that the normal flora of the lid and conjunctiva may be the source of the offending organisms. Prolonged use of topical steroids and antibiotics necessary for postoperative control of inflammation following cataract surgery may result in selection of more virulent forms of organisms which then

invade the cornea.

Suture-related abscesses can progress to perforation and endophthalmitis despite aggressive treatment with fortified antibiotics. Surprisingly the ulcer in this patient healed without perforation. This could be because antibiotic treatment had been started at a general clinic prior to presentation to the eye clinic

Understanding risk factors for the development of suture-related corneal abscess is crucial in informing decision as to what surgical steps to take in a particular patient. Proper preoperative preparation, sterile intraoperative technique, meticulous wound construction and closure, early post-operative removal of corneal or limbal suture and prompt recognition and treatment of infection can reduce the incidence and effect of this rare but devastating complication of uneventful cataract surgery.

### Acknowledgements

We wish to thank the nursing staff of the Eye Unit Juba Medical Complex for their support in the collection of information and preparation of this manuscript.

### Disclaimer

The author declares that there is no conflict of interest in the production of this article

### References

1. Ammar MA, Samar A, Ashley B. Clear corneal incisions in cataract surgery. *Middle East Afr J Ophthalmol*. 2014 Jan-Mar; 21(1): 25-31
2. Takashi S, Hirotohi L, Toshihiko U, et al Suture-related keratitis caused by *Corynebacterium macginleyi*. *J Clin Microbiol*. Nov 2007 45(11): 3833-3836
3. Siganos CS, Solomon A and Frucht-Percy J. Microbiol findings in suture erosion after penetrating keratoplasty. *Ophthalmology* Mar; 104(3): 513-6
4. Lee JB, Smith SD and Jeng BH Suture related corneal infection after clear corneal cataract surgery. *J Cataract and Refract Surg* 2009;35: 939-942
5. Turkyilmaz K, Kurt A, Dilek AR, Sekeryapan B and Erturk AA case of suture related bacterial keratitis and its treatment with topical imipenem. *J Ocul Biol Infor*. Dec 2011; 4(4): 141-144
6. Ahmad BT, Steinemann T. Suture related keratitis following cataract surgery caused by methicillin resistant staphylococcus aureus. *J Clin Ophthalmol* 2010;4 179-182.
7. Charteris DG, Batterbury M, Armstrong M and Tulio AB. Suppurative keratitis caused by streptococcus pneumoniae Br J ophthalmol. Nov 1994 78(11): 847-849
8. Cameron JA and Huamann A. Corneoscleral abscess resulting from broken suture after cataract surgery. *J cataract Refract Surg*. 1994;20: 82-83.