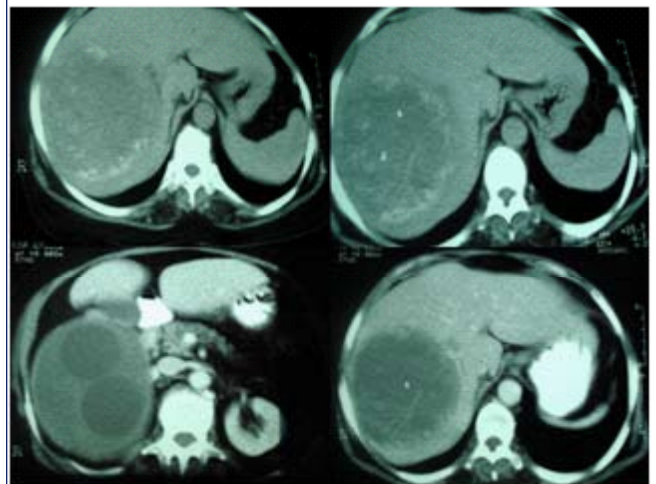


QUIZ FOR OUR READERS

Lady with fever and hepatomegaly

Case: 54 year old female from an urban area presented with low grade fever, and vague right upper quadrant abdominal discomfort of one month duration. She was a sweeper by profession and had no close contact with pets. On examination she was febrile; the vital signs were stable and she had no jaundice or other stigmata of chronic liver disease. The liver was palpable to 7cms below the right costal margin and 4cms in the epigastrium with a smooth surface, and was tender to palpation: there were no bruits. Her haemogram and biochemical parameters were normal except for elevated alkaline phosphate levels (323 IU/L). These were the contrast enhanced computerized tomography images (see image).



Questions:

- Q1. What is the likely diagnosis?
- Q2. What other conditions should be considered?
- Q3. What is the most likely causative organism?
- Q4. What is the most serious complication of this condition?
- Q5. Are there any serological tests that would aid diagnosis?
- Q6. What is the gold standard treatment of the condition?
- Q7. Which is the preferred drug for the treatment of the condition?

Quiz sent by George Sarin Zacharia