

Penetrating arrow in the face: a case report

Ernesto Carmona Fernández

1st Degree Specialist in Oral and
Maxillofacial Surgery. Department of
Dentistry. Intermediate Hospital Oshakati.
Namibia.

Correspondence:

Ernesto Carmona Fernández
ernesto847@yahoo.com

Submitted: June 2020

Accepted: September 2020

Published: November 2020

Abstract

Cases in which a foreign body is embedded in the maxillofacial region are uncommon and rarely reported. Our case is an unusual one of an arrow stuck in the face (in the naso-orbitoethmoid and maxillary region) during a fight resulting in severe pain and discomfort. To our knowledge, impaction with this type of foreign body has not been previously reported.

The patient was successfully treated, using a multidisciplinary approach, with the patient assessed and treated by a variety of specialists.

Keywords: Maxillofacial trauma; retained foreign body; penetrating injury, Namibia

Introduction

Foreign bodies embedded deep in facial tissues present a challenge to maxillofacial surgeons. These cases may result from trivial accidents, gunshot, industrial accidents, interpersonal violence, and knife impactions.

Approximately one third of all foreign bodies are missed during initial examination. Foreign bodies like grit particles, wooden pieces, thorns, pebbles, or glass particles may get embedded into deep facial tissues which are detected only accidentally either with the help of radiographs or at a later stage when a patient presents with some signs and symptoms like pain, pus discharge, sinus formation etc. However, some cases represent real emergencies if the foreign body is located near vital structures such as the eye.

Foreign bodies in the face pose a diagnostic challenge due to their size, difficulty of access and their close relation to vital structures. Ocular acuity and mobility should be investigated on admission as they are frequently associated with ocular trauma.

Case Report

A 30-year-old male presented to the Intermediate Hospital Oshakati (IHO) complaining of pain and discomfort on the face and left eye following a fight with another man while drinking in a bar. He came straight to the hospital, was given analgesics, and anti-tetanus prophylaxis, and admitted to the maxillofacial ward. Posterior-anterior (PA) and lateral (LV) X-rays of the skull showed a radiopaque object about 23cm in length in the facial bones, involving the internal orbital wall, nasal and ethmoid bones, right maxillary bone and right temporomandibular joint. (Figure 1).

The left eye was assessed in the Ophthalmology Department a day after injury when no abnormalities were detected and the maxillofacial surgeon continued the management.

Clinical examination showed a foreign body stuck in the internal angle of the left eye, no bleeding was detected or any sign of eye injury or functional problems. The orbital rims were intact and non-tender on palpation. The globe of the eye was intact and vision was normal in both eyes. Eye movements were not restricted and there was no diplopia in all gazes. There was severe pain and restricted mouth opening to 2.5cm, caused by the injury.

Citation:

Fernandez. Penetrating arrow in the face: a case report. *South Sudan Medical Journal* 2020;13(4):163-166

© 2020 The Author (s)

License: This is an open access article under [CC BY-NC-ND](https://creativecommons.org/licenses/by-nc-nd/4.0/)

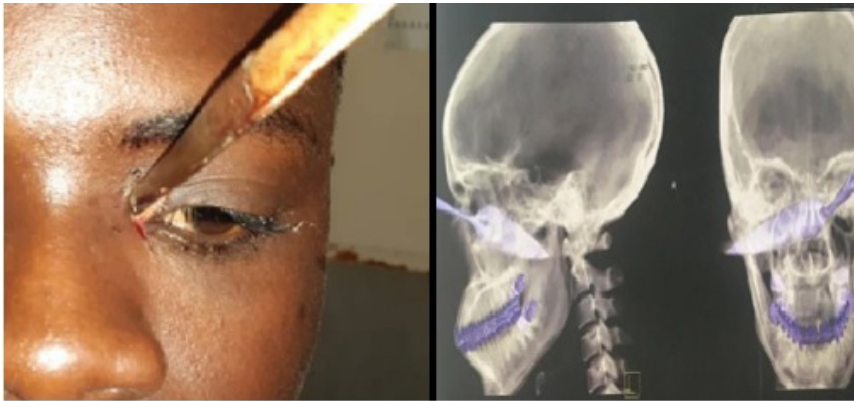

Figure 1. Preoperative view PA and LV X-rays of the skull

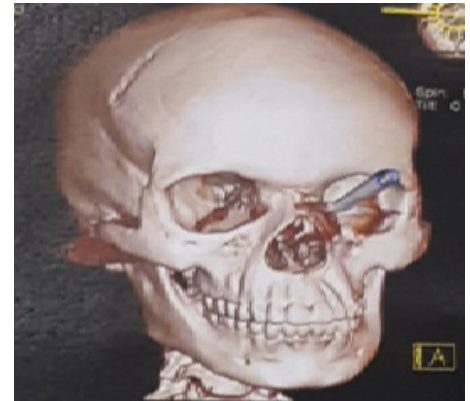


Figure 2. 3D CT scan showing foreign body involving orbital, naso-orbitoethmoid and maxillary region causing fracture of the right zygomatic arch

A computed tomography (CT) scan with 3D reconstruction was done to assess the extent of the injury and the tissues involved (Figure 2). Angiography was not possible because the patient, being a foreigner, would have had to pay for this. The CT showed a metal object in the orbit, which was extending into the naso-orbitoethmoid region, upper maxilla and right temporomandibular region. A right zygomatic arch fracture was detected but, as it had no displacement, no treatment was needed. A neurosurgical opinion was that there were no intracranial lesions.

Surgery was performed on the third day of admission under general anaesthesia and endotracheal intubation. Prophylactic antibiotics was started one hour before the operation with cefuroxime 1500 g and continued every 8 hours 750 g on the day of the surgery.

The neck on the right side was opened with an incision of 6 cm following the anterior border of the sternocleidomastoid muscle in order to access the external carotid artery and pass a loose ligature to deal with severe bleeding in case it was impossible to manage locally. A local anaesthetic with adrenaline was injected in the area of the laceration prior to making an incision through the internal wall of the left orbit, surrounding the foreign body, extending for about 6 cm. A careful dissection through the soft tissue layers was made down to the bone, exposing the entrance of the object being careful not to displace it. (Figure 3).

Naso-orbital osteotomy was performed with a micromotor and a surgical bur, similar to the one we use in third molar surgery and osteotomies, in order to make the entry wound wider and allow the gentle removal of the object with forceps. (Figure 4). As no significant bleeding occurred, the bone was filled with a similar bur but with the active part round, similar to those prosthodontics use for dentures, and the wound was irrigated with hydrogen peroxide 3%, and betadine 10%. The wound was closed

by layers in the orbit with vicryl 3-0 and nylon 4.0. Tarsorrhaphy was performed to protect the eye for the first two days.

The neck was sutured by layers with chromic 3-0 and nylon 3.0. A corrugated drainage was left in the wound for 2 days.

The orbital region was also sutured the same way and tarsorrhaphy was performed (Figure 5).

Postoperative recovery was successful and the patient was discharged after one week (Figure 6).

Discussion

It is not easy for maxillofacial surgeon to diagnose the presence of foreign bodies at the initial examination clinically. Approximately one-third of all foreign bodies are initially missed.^[51] Many cases of embedded foreign bodies go unnoticed at initial examination and reveal their presence at a later stage when patient revisit the surgeon with some complaints with the associated area. Often foreign bodies are detected as an additional finding on radiographs, which were basically advised for ruling out bony injuries.

Retained foreign bodies following penetrating injury to the maxillofacial region by an arrow are uncommon and rarely reported. We have found reported cases in South Africa^[12], USA^[3] and elsewhere.^[4-12]

Management of injuries, caused by a foreign body like an arrow, to the maxillofacial region should be thorough and systematic requiring a multidisciplinary approach including ophthalmology, otolaryngology, neurosurgery and maxillofacial surgery. Initial airway and haemodynamic stabilization of the patient should be established with

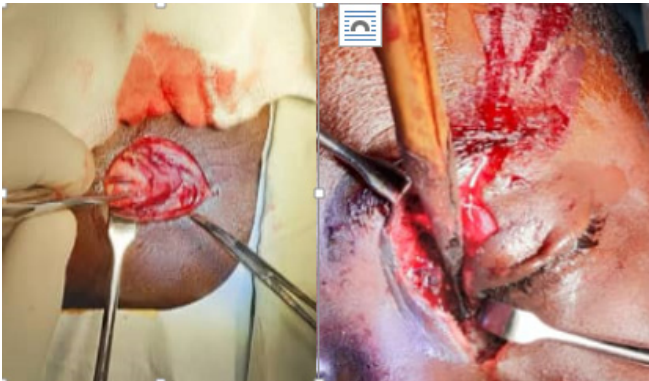


Figure 3. Dissection to access the carotid artery and the bone surrounding the foreign body



Figure 4. Foreign body extracted from the wound.

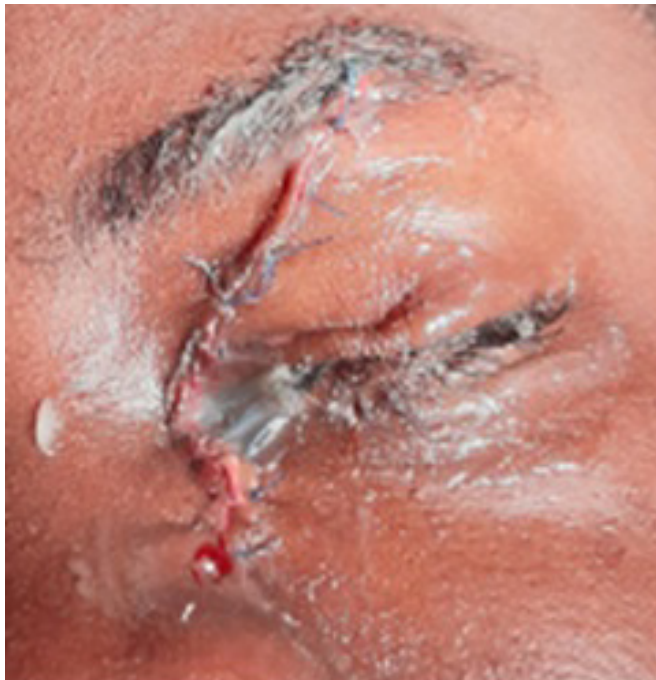

Figure 5. Tarsorrhaphy on the left eye.

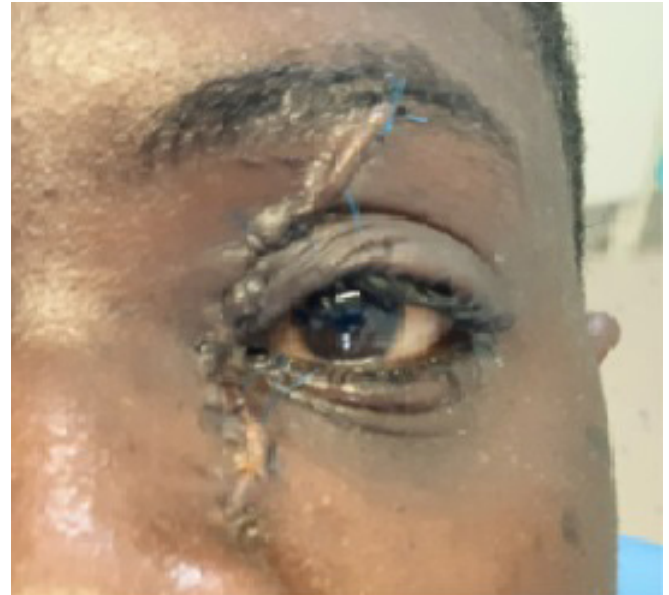

Figure 6. Satisfactory postoperative progression

assessment of damage to vital structures. Then appropriate laboratory and radiographic investigations may be performed. A detailed history of the events leading to the injury should be obtained from the patient, witnesses, or family. This should reduce the chance of a penetrating injury being overlooked. Complete examination of the head and neck region should be performed, with care taken to explore any wounds that appear more than superficial. Patients may often present with other knife wounds to the hands and thoraco-abdominal areas.

Radiographic examination is essential with any clinical evidence or suspicion of a retained foreign body. As a minimum, two plain radiographs taken at right angles should be obtained in order to identify the location of the foreign body in relation to vital structures.^[1-4]

Computed tomography (CT) is usually the first line of imaging performed in cases of deeper penetrating injuries, particularly when attempting to detect metallic foreign bodies.^[5, 6] In cases where plain film or CT may not be immediately available, ultrasonography has been documented to be useful in foreign body detection.^[7]

Thorough knowledge of the vascular anatomy of the maxillofacial region is especially important. If a foreign body, such as a retained knife blade, is visualized on plain films or CT, angiography may be indicated.^[8] While catheter angiography is the standard of care in the identification of vascular injuries, CT angiography is an alternative approach.^[9] Many major vessels are present in the maxillofacial region, and damage to the vasculature should be initially suspected until proven otherwise.

Even if significant bleeding is not present on initial examination, the foreign body may cause disruption of the vessel walls, causing development of pseudoaneurysms. If disrupted during foreign body removal, these may result in severe bleeding.^[10] The surgeon may consider consulting interventional radiology or vascular surgery in the event a problem during retrieval of the object and selective embolization or surgical ligation of the associated vessels

may be necessary. In this respect, we decided to access the external carotid artery placing a loose ligature to be used in the event of serious hemorrhage.

Surgical management of patients sustaining penetrating wounds to the maxillofacial region with retained foreign bodies depends on clinical and radiological findings and of course on the composition and type of foreign body, size, location, and relationship to local structures. The ideal method of removing a retained knife blade is careful extraction through the initial entrance wound under general anaesthesia.^[11] Care should be taken to avoid trauma to adjacent structures during withdrawal, especially if the blade is serrated. Thorough exploration of the wound after foreign body removal should then be performed with copious irrigation of the site. When indicated, tetanus prophylaxis and appropriate perioperative antibiotics should be administered.^[12]

As seen in this case, the initial history of the associated trauma is often inaccurate or incomplete, especially when alcohol consumption or intoxication is involved. Physical findings may not entirely correlate with the reported nature of the injury or predisposing event.

References

1. Voss JO, Thieme N, Doll C, et al. Penetrating Foreign Bodies in Head and Neck Trauma: A Surgical Challenge. *Craniomaxillofac Trauma Reconstr.* 2018;11(3):172–182. <https://www.ncbi.nlm.nih.gov/pmc/articles/PMC6078685/>
2. M2ohortloane GP, Mabongo M. Unusual intraorbital foreign body impactions. A case report. *S Afr Dent J.* 2019 Feb; 74(1): 32-34. http://www.scielo.org.za/scielo.php?script=sci_arttext&pid=S0011-85162019000100007&lng=en
3. Jones J, Guglielmi M, Brooks SR. Penetrating Facial Injury with Retained Knife Blade: A Case Report. *Clin Surg.* 2017;2:1411. <http://www.clinicsinsurgery.com/full-text/cis-v2-id1411.php>
4. Poghosyan AY, Gevorgyan AS, Martirosyan A. Impacted Foreign Body in the Infratemporal Region: Case Report. *Journal of Surgery [Jurnalul de chirurgie].* 2015; 11(4): 161-163. <https://www.hilarispublisher.com/open-access/impacted-foreign-body-in-the-infratemporal-region-case-report-1584-9341-11-4-4.pdf>
5. Mithilesh KV. Foreign Bodies in Maxillofacial Trauma: 4 Case reports. *IOSR Journal of Dental and Medical Sciences (IOSR-JDMS)* 2018;17(10), 2018:38-42. <https://www.iosrjournals.org/iosr-jdms/papers/Vol17-issue10/Version-2/J1710023842.pdf>
6. Melo MN, Pantoja LN, De Vasconcellos SJ, Sarmento VA, & Queiroz, CS. Traumatic Foreign Body into the Face: Case Report and Literature Review. *Case reports in dentistry* 2017. <https://doi.org/10.1155/2017/3487386>
7. Blackhall KK, Laraway DC. Penetrating retro-orbital foreign body – large glass shards: A maxillofacial surgery case report. *SAGE Open Medical Case Reports.* <https://doi.org/10.1177/2050313X15622890>
8. Aregbesola SB, Ugboko V I. Unusual foreign bodies in the orofacial soft tissue spaces: A report of three cases. *Niger J Clin Pract [serial online]* 2013; 16:381-5. <http://www.njcponline.com/text.asp?2013/16/3/381/113469>
9. Sanadi SA, Sabina A, Yasser Al-Thobaiti SD, et al. Longstanding Unrecognized Wooden Foreign Bodies in Oro-facial Region, Report of three Cases. *American Journal of Public Health Research.* 2015; 3(4):157-161. <http://www.sciepub.com/AJPHR/abstract/4591>
10. Balakrishna R, Jannu A, Sudarshan Veena GC. Unexpected Foreign Body in Neck: A Case Report. *Ann Clin Case Rep.* 2017;2:1290. <http://www.anncaserep.com/full-text/accr-v2-id1290.php>
11. Auluck A, Behanan A, Pai K, et al. Recurrent sinus of the cheek due to a retained foreign body: report of an unusual case. *Br Dent J* 2005;198:337–339. <https://doi.org/10.1038/sj.bdj.4812172>
12. Vinayagam R, Gita B, Chandrasekaran S, Nazer AI. Traumatic impaction of foreign body in the mucobuccal fold of lower anterior region in the oral cavity: A chance finding. *J Indian Soc Periodontol* 2015;19:339-41. <http://www.jisponline.com/text.asp?2015/19/3/339/153485>