

Case Report: Ultra-Short Bowel Syndrome after a near-total small bowel resection for gangrene due to volvulus in a district hospital in South Sudan

Koma Akim

General Surgeon/Health Coordinator, St.
Theresa Mission Hospital, Isohe, Caritas Torit,
Torit State, South Sudan,

Correspondence:
Koma Akim,
akimkoma@gmail.com

Submitted: April 2019
Accepted: June 2019
Published: August 2019

Introduction

The length of the small intestine ranges between 3m-10m with an average of 6.5m.^[1] It is made up of the duodenum (25cm), jejunum (1.5m), and ileum (distal three fifths). Resection of up to a third or even half is compatible with a normal life. However, survival has been reported with a small bowel length of only 45 cm.^[2] A major resection leads to the small gut syndrome of malabsorption of macro and micro nutrients.^[3] The classical symptoms are diarrhoea and those arising from malabsorption. Long term survival is enhanced with the use of parenteral nutrition^[4] but there are no publications of survival without parenteral nutrition. Small bowel volvulus causing gangrenous bowel is one of the commonest reasons for major small bowel resection.^[5] This case report highlights the survival of a patient who had major small bowel resection, developed ultra-short gut syndrome (USBS) and the challenges in managing the patient.

Case presentation

The case is of a 15-year-old female pupil at a local primary school. She had been sick for more than three months frequently attending various hospitals and outpatient clinics with no improvement. For five days before her admission, she complained of abdominal pain, constipation, abdominal distention, vomiting, dizziness, easy fatigability and palpitations. There were no other symptoms from a systematic enquiry. Menstrual cycles had not begun. There was no history of prior abdominal surgery.

The patient looked unwell, lying motionless, in moderate pain, very pale, not jaundiced, no lymphadenopathy but mildly dehydrated. Her blood pressure was 106/70mmHg, and the pulse rate was 108/min, respiratory rate of 21/min, temperature of 37.7°C. The abdomen was symmetrical, not moving with respiration, with generalized tenderness, guarding, rebound tenderness, board-like rigidity, moderately distended, and absent bowel sounds. The rectum was empty on digital examination.

The differential diagnosis included peritonitis secondary to perforated bowel, intestinal obstruction secondary to volvulus and a ruptured ectopic pregnancy.

Facilities for an abdominal X-ray were not available but an ultrasound scan showed intestinal obstruction with peritoneal fluid. Haemoglobin was 11g/dl and urine HCG was negative. Other laboratory tests were not possible. After blood grouping two units of blood were held on standby.

Preoperative management

The patient was kept nil by mouth, given antibiotics (intravenous ceftriaxone 1g stat, intravenous metronidazole 500mg stat, intravenous gentamicin 80mg stat), analgesia (intravenous tramadol 100mg stat), intravenous fluids (IVF Ringers Lactate 1.5 litres in 6 hours, intravenous dextrose 50mls of 50% stat), naso-gastric tube (NGT), urethral catheter.

Citation:

Akim, Case report: Ultra-Short Bowel Syndrome after a near-total small bowel resection for gangrene due to volvulus in a District Hospital in South Sudan, South Sudan Medical Journal 2019; 12(3):112-114

© 2019 The Author (s)

License:

This is an open access article under

[CC BY-NC-ND](https://creativecommons.org/licenses/by-nc-nd/4.0/)

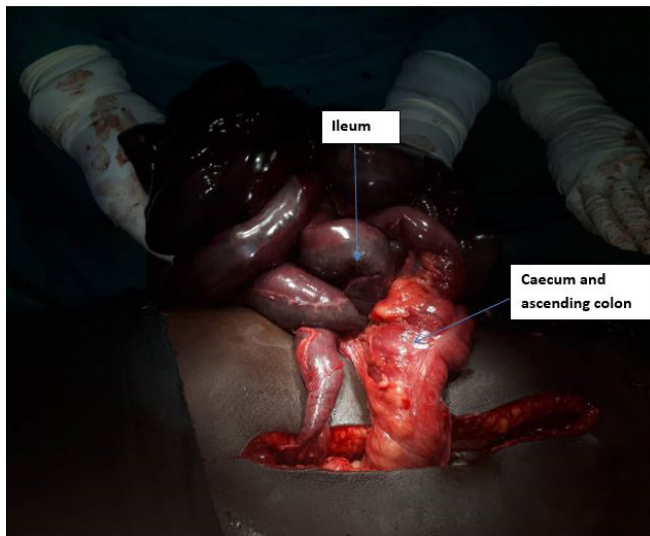


Figure 1. Note the gangrene involving the caecum and ascending colon (credit Dr Bulus Lawrance)

Intraoperative management

After almost four hours resuscitative measures an emergency laparotomy via a midline incision was carried out under ketamine anaesthesia. The small bowel was covered with gangrenous omentum with a volvulus twisted through 270 degrees. Almost all of the small bowel and about 10cm of the caecum and the ascending colon were gangrenous. There were about 150 mls of dark brown peritoneal fluid. There were no viscus perforations. A near total small bowel resection and a limited right hemicolectomy were done. She was left with a jejunum of approximately 5 cm and a jejuno-transverse colonic primary anastomosis. The intraoperative findings are as shown in Figures 1 and 2.

Postoperative management and progress

The patient continued with a NGT and nil by mouth, intravenous fluids (Ringers lactate 3litres in 24hours for a week, intravenous 50% dextrose 50mls four hourly for a week), antibiotics (intravenous ceftriaxone 1g daily for a week, intravenous metronidazole 500mg three times a day for a week, intravenous gentamicin 80mg three times a day for a week, proton pump inhibitor (intravenous pantoprazole 20mg daily for week) to reduce gastric hypersecretions and analgesia (intravenous tramadol 50mg three times a day for a week).

The first three days were uneventful. However, on days 4-6 she developed watery diarrhoea and vomiting. On day 7 the surgical site was found to be infected with a degree of wound dehiscence. On day 10 she developed a minor anastomotic leak which was managed conservatively (daily dressing of the wound, allowing free drainage of the fluid, kept her nil by mouth, she was put on intravenous fluids i.e. Ringers lactate 3 litres daily alternating with 5% dextrose). The anastomotic leak healed after about four

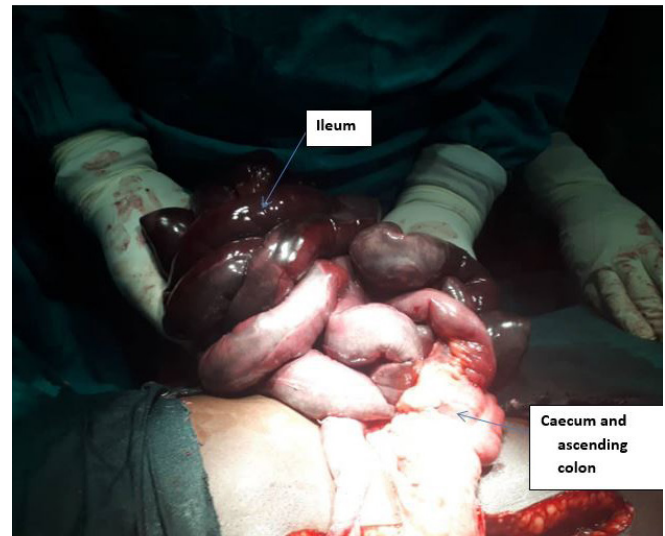


Figure 2. Derotation of the small bowel volvulus (credit Dr Bulus Lawrance)

weeks. She was discharged 3 weeks after her operation and reviewed at least weekly whenever necessary.

Approximately, about a month later after the operation, she was in a fair general condition but started exhibiting signs and symptoms of malnutrition which included weight loss, loss of muscle mass, dry and flaky skin, peripheral lower limbs oedema, malaise and generalized body weakness. She had started on the family diet (given every 4-6 hours) a fortnight after surgery. However, because she was eating very little she was also put on Corn Soya Blend (CSB), three times daily. CSB is a fortified blended food supplement, consisting of maize and soya flour fortified with vitamins and minerals, used to treat malnutrition.

The second and third months post operatively were characterized by sporadic episodes of diarrhoea and vomiting. She received home-made mango and orange juice and sometimes drank milk. She was also put on about 1.5 litres of intravenous Ringers lactate while at home supervised by an aunt who was a nurse. The aunt was reported to have tried giving ORS but, due to persistent vomiting, she stopped and gave Ringers lactate to which she had access.

Around two and half months after surgery, the girl developed a persistent cough for almost two weeks. The plan was to investigate her for tuberculosis. However, the only X-ray machine malfunctioned and therefore the CXR could not be done. Sputum for AAFBs was also planned, but this too did not materialized because of the IDD holidays.

Three months after the surgery she was brought to the hospital with a one-week history of persistent postprandial vomiting (containing the food eaten, not blood stained) and watery diarrhoea (not blood stained) three to four

times in a day. On examination, she was ill-looking, cachectic, severely dehydrated, not jaundiced and mildly pale.

Respiratory system examination: Respiratory rate of 21/min, some crepitations but no bronchial breathing. Cardiovascular examination: Pulse rate 113/min weak and thready, BP 90/50mmHg, no heave, no thrill, heart sound 1 and 2 heard, there was no murmur. Abdomen examination: Moving with respiration, a midline scar, reduced skin turgor, no tenderness, bowel sounds were present. Because of these features of hypovolaemia she was started on intravenous Ringers lactate: 1 litre over 10-15 minutes and 1.5litres 4 hourly. Sadly, however, she died approximately six hours after admission. Unfortunately in Torit Town we did not have access to biochemical measurements so cannot comment on her electrolyte and renal function.

We were initially encouraged by the progress of this patient but the outcome demonstrates how serious USBS is and how difficult it is to manage especially without extensive resources.

Discussion

The near total resection of the small intestine in this patient resulted into USBS with approximately less than 10cm of small bowel remaining.^[6] The symptoms of USBS are diarrhoea, vomiting, abdominal pain, weight loss and extreme fatigue. The morbidity and mortality rates associated with USBS are higher than those for short bowel syndrome. Short bowel syndrome is associated with a reduced quality of life and mortality of 10-15 % over 5 years.^[7] The survival of patients with USBS without TPN and / or small bowel transplant is not known.

Challenges to treating USBS in South Sudan

a. Diagnostic: The investigative and diagnostic capability of the hospital laboratory and radiology services are limited because of malfunction and financial constraints.

b. Economic: Total Parenteral Nutrition (TPN) is not generally available in South Sudan. Even when TPN is obtainable it is very expensive (about US\$ 300 per day) and beyond the reach of most people.

c. Social: Attendance at school and relationships outside and within the family setting have been disrupted.

d. Advances in treatment: Total Parenteral Nutrition (TPN) is a bridge to small bowel transplantation but in South Sudan such care is not possible.

References

1. Ellis H, Mahadevan V. *Clinical anatomy: applied anatomy for students and junior doctors*: Wiley-Blackwell; 2018.
2. Liu M-Y, Tang H-C, Yang H-L, Chang S-J. A Short Bowel (Small Intestine= 40 cm), No Ileocecal Valve, and Colonic Inertia Patient Works Well with Oral Intake Alone without Parenteral Nutrition. *Case reports in surgery*. 2014;2014.
3. O'keefe SJ, Buchman AL, Fishbein TM, Jeejeebhoy KN, Jeppesen PB, Shaffer J. Short bowel syndrome and intestinal failure: consensus definitions and overview. *Clinical Gastroenterology and Hepatology*. 2006;4(1):6-10.
4. Wilmore DW, Dudrick SJ. Growth and development of an infant receiving all nutrients exclusively by vein. *Jama*. 1968;203(10):860-4.
5. Sala D, Chomto S, Hill S, editors. Long-term outcomes of short bowel syndrome requiring long-term/home intravenous nutrition compared in children with gastroschisis and those with volvulus. *Transplantation proceedings*; 2010: Elsevier.
6. Dore M, Junco PT, Moreno AA, Cerezo VN, Muñoz MR, Galán AS, et al. Ultrashort bowel syndrome outcome in children treated in a multidisciplinary intestinal rehabilitation unit. *European Journal of Pediatric Surgery*. 2017;27(01):116-20.
7. DeLegge M, Alsolaiman MM, Barbour E, Bassas S, Siddiqi MF, Moore NM. Short bowel syndrome: parenteral nutrition versus intestinal transplantation. Where are we today? *Digestive diseases and sciences*. 2007;52(4):876-92.